

Dermscopy of Abortive Hemangioma: Morphological Study of 11 Cases

Leopoldo Fernández-Domper¹, Esmeralda Silva Diaz¹, Manuel Ballesteros Redondo¹, Jose Maria Martin Hernández¹, Angeles Revert Fernández¹

¹ Department of Dermatology, Hospital Clínico Universitario, University of Valencia, Valencia, Spain

Key words: abortive hemangiomas, dermoscopy, infantile hemangiomas, vascular anomalies

Citation: Fernández-Domper L, Silva Diaz E, Ballesteros Redondo M, Martín Hernández JM, Revert Fernandez A. Dermoscopy of Abortive Hemangioma: Morphological Study of 11 Cases. *Dermatol Pract Concept.* 2023;13(2):e2023098. DOI: <https://doi.org/10.5826/dpc.1302a98>

Accepted: August 31, 2023; **Published:** April 2023

Copyright: ©2023 Fernández-Domper et al. This is an open-access article distributed under the terms of the Creative Commons Attribution-NonCommercial License (BY-NC-4.0), <https://creativecommons.org/licenses/by-nc/4.0/>, which permits unrestricted noncommercial use, distribution, and reproduction in any medium, provided the original authors and source are credited.

Funding: This research was supported by the Dermatology Department of the Clinical University Hospital of Valencia.

Competing Interests: None.

Authorship: All authors have contributed significantly to this publication.

Corresponding Author: Leopoldo Fernández-Domper, MD, Department of Dermatology Hospital Clínico Universitario de Valencia, Blasco Ibañez Avenue, 17, Valencia, Comunidad Valenciana, 46010, Spain Tel: +34636683965 E-mail: lfernandezdomper@gmail.com

Introduction

Abortive hemangiomas (AH) or minimal or arrested growth hemangiomas constitute a distinct subgroup of infantile hemangioma (IH) with a characteristic clinical presentation and natural history that are often clinically confused with other vascular anomalies (VA) [1,2]. Dermoscopy can be a useful tool for distinguishing VAs that may be clinically similar such as IH precursor lesions, port wine stains (PWS) and, probably, AH [3]. However, dermoscopy pattern of AH has only been previously described by Toledo-Alberola et al in 2 cases [4].

Case Presentation

The aim of this study was to evaluate the dermoscopy findings of an AH single-center case series, comparing these findings with those described in other clinically similar VAs such as IH precursor lesions and PWS. We evaluated the dermoscopy patterns and structures of 11 consecutive clinically

diagnosed AH cases in our pediatric dermatology department, assessed during 2021, and we compared these findings with those described for IH precursor lesions and PWS.

Clinical and demographic findings are summarized in Table 1. Serpiginous or tortuous vessels, punctate vessels and vascular lacunae were observed in 100% of the cases clinically diagnosed as AH (Figures 1 and 2).

Conclusions

AH is a distinctive variant of IH present from birth in most cases, and, with little ability to proliferate. Although they could be clinically similar to other VAs they have different morphologic and immunostaining patterns. On histology, they show dilated thin-walled vessels within the superficial dermis, with a GLUT-1 positivity immunostaining demonstrating a clear distinction between AH and PWS or congenital hemangiomas [1,2]. Dermoscopic examination may facilitate the identification of AH for early diagnosis and treatment. In our case series, serpiginous or tortuous

Table 1. Clinical and demographic findings.

Patient	Demographic characteristics				Dermoscopy findings					
	Age at diagnosis (years)	Age occurrence	Sex	Location	Treatment	Associate lesions	Additional tests	Serpiginous/tortuous vessels	Punctiform vessels	Vascular lacunae
1	6	First days	M	Right leg	Timolol	-	-	Yes	Yes	Yes
2	1	Unknown	M	Left buttock	Timolol	Infantile hemangioma	-	Yes	Yes	Yes
3	2	Birth	F	Left knee	Timolol	-	Echography and doppler	Yes	Yes	Yes
4	2	Birth	M	Left thigh	Timolol	-	-	Yes	Yes	Yes
5	0	Birth	F	Sacral fossa		-	Spinal echography	Yes	Yes	Yes
6	1	Birth	F	Right external malleolus	Timolol	-	-	Yes	Yes	Yes
7	1	Birth	F	Left hand	Timolol	-	Soft tissue Echography	Yes	Yes	Yes
8	14	Unknown	M	Abdomen		-	-	Yes	Yes	Yes
9	6	First days	F	Right lumbar	Timolol + Propranolol	-	-	Yes	Yes	Yes
10	2	Birth	M	Neck		-	-	Yes	Yes	Yes
11	1	Birth	F	Right thigh	Timolol	-	-	Yes	Yes	Yes

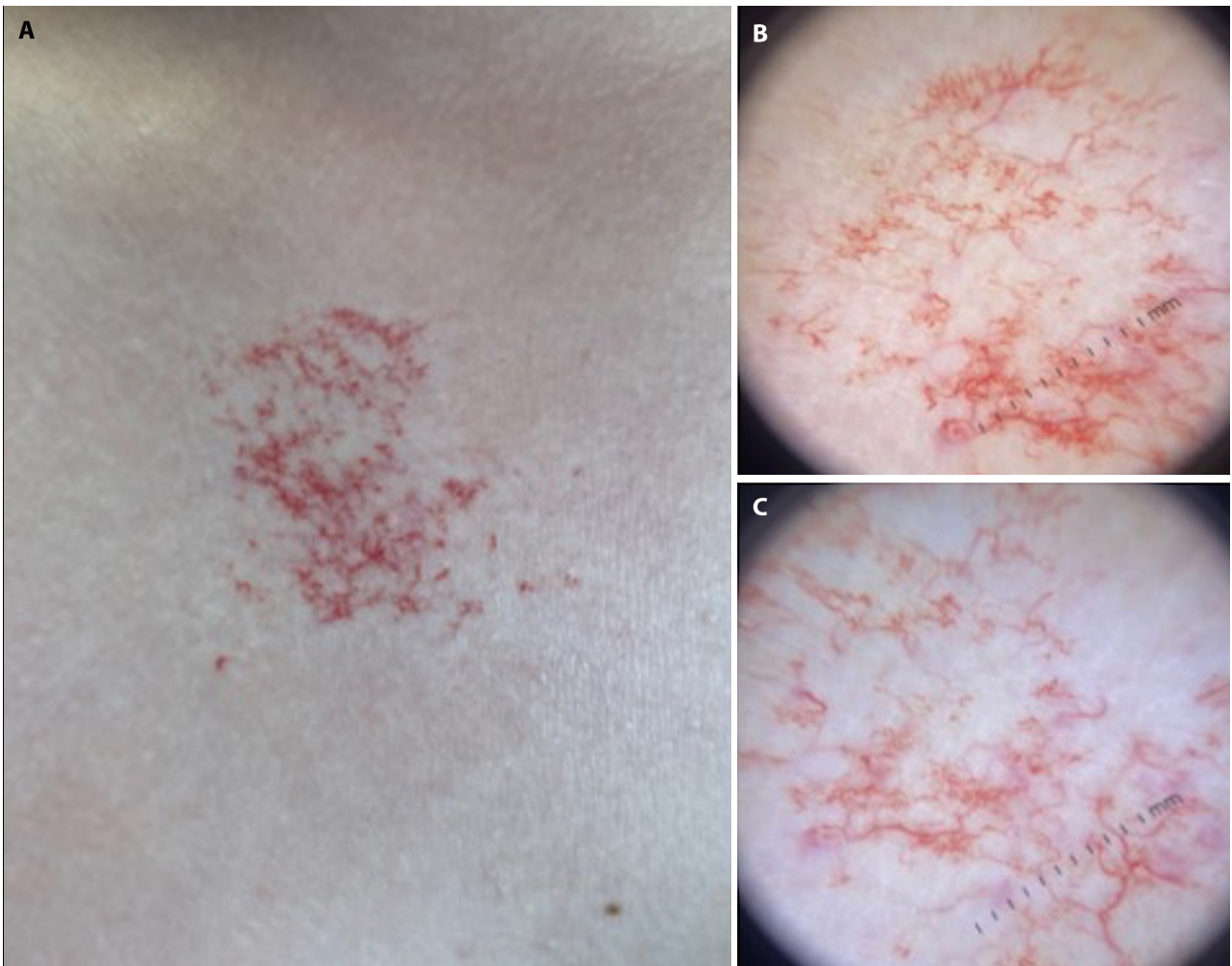


Figure 1. (A) Clinically macule with telangiectasias erythematous background. (B,C) Dermoscopy image showing serpiginous or tortuous vessels, punctate vessels and vascular lacunae.

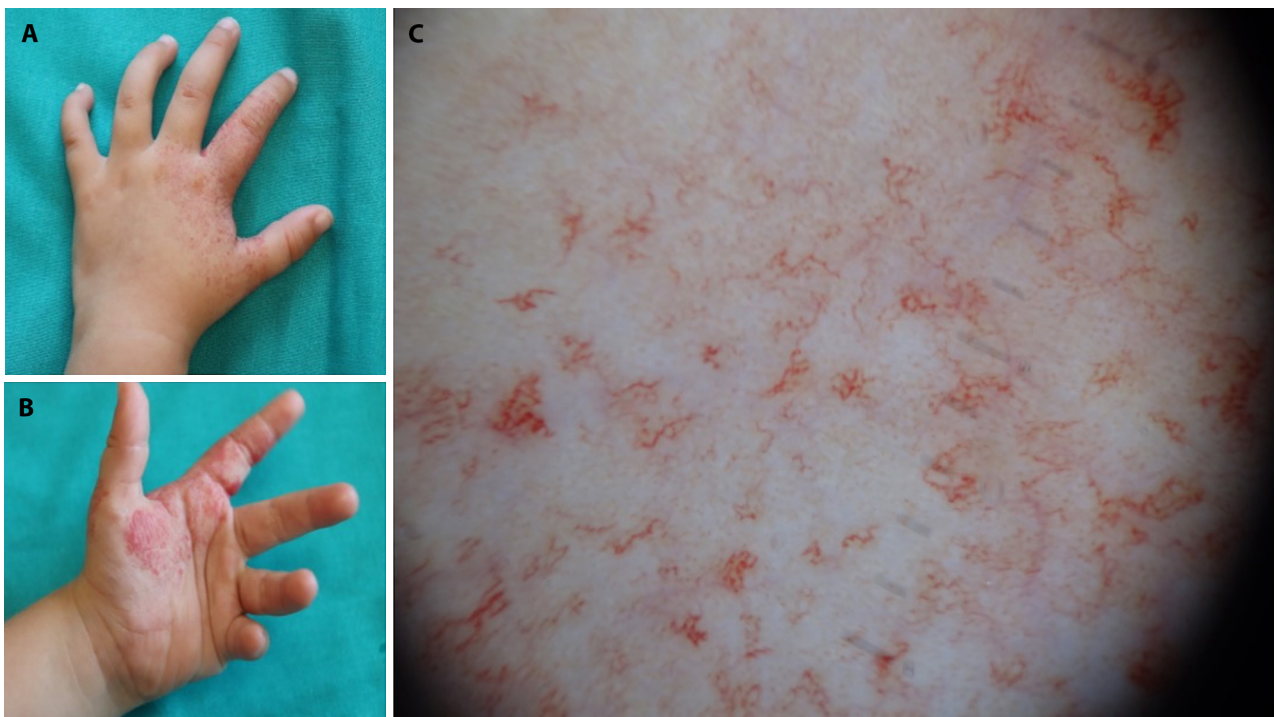


Figure 2. (A,B) Telangiectasias on an erythematous or reticulated background. (C) Dermoscopy image showing serpiginous or tortuous vessels, punctate vessels and vascular lacunae.

vessels, punctate vessels and vascular lacunae was observed in 100% of the cases clinically diagnosed as AH. IH precursor lesions dermoscopy features have been described as large linear vessel and branching vessels with erythematous background [5]. On the other hand, linear vessels, reticular vessels, sausage-like vessels, dots or globules vessels and mixed vessels, as well as white circles and whitish veil have been described in PWS [6]. When comparing our findings in AH, with those described IH precursor lesions and PWS, we found these to be differential and characteristic of AH. As limitations, no control group was included, therefore, no definitive conclusions could be made.

Dermoscopy might improve the clinical diagnosis of AH. It might help distinguish AH from IH precursor or PWS. More studies including other lesions are needed to confirm our findings.

References

1. Martin JM, Sanchez S, González V, Cordero P, Ramon D. Infantile hemangiomas with minimal or arrested growth: A retrospective case series. *Pediatr Dermatol.* 2019;36(1):125–131. DOI: 10.1111/pde.13695. PMID: 30318787.
2. Rodríguez Bandera AI, Sebaratnam DF, Wargon O, Wong L-CF. Infantile hemangioma. Part 1: Epidemiology, pathogenesis, clinical presentation and assessment. *J Am Acad Dermatol.* 2021;1379–1392. DOI: 10.1016/j.jaad.2021.08.019. PMID: 34419524.
3. Piccolo V, Russo T, Moscarella E, Brancaccio G, Alfano R, Argenziano G. Dermatoscopy of Vascular Lesions. *Dermatol Clin.* 2018;36(4):389–395. DOI: 10.1016/j.det.2018.05.006. PMID: 30201148.
4. Toledo-Alberola F, Betlloch-Mas I, Cuesta-Montero L, et al. Abortive hemangiomas. Description of clinical and pathological findings with special emphasis on dermoscopy. *Eur J Dermatol.* 2010;20(4):497-500. DOI: 10.1684/ejd.2010.0959. PMID: 20400393.
5. Sun Y, Hu SCS. Dermoscopy as a diagnostic aid in the precursor stage of infantile hemangioma. *Int J Dermatol.* 2022;61(2):e54–e55. DOI: 10.1111/ijd.15841. PMID: 34363688.
6. Huang Y, Yang J, Li Z, Zhang L, Sun L, Bi M, Wang L. Dermoscopic features of port-wine stains: A study of 264 cases. *Australas J Dermatol.* 2021;62(2):e201-e206. DOI: 10.1111/ajd.13470. PMID: 32955124.