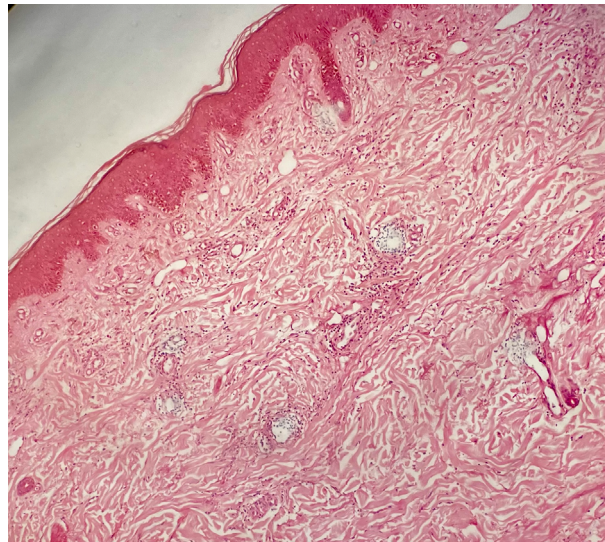


## Successful Treatment of Morpheaform Graft-Versus-Host Disease: A Dermoscopic Follow-up of 1 Year

Rohit Kothari<sup>1</sup>, Shekhar Neema<sup>2</sup>, Anuj Bhatnagar<sup>3</sup>, Karthi Kishore<sup>4</sup>, Jeenu Varghese<sup>5</sup>



**Supplementary Image:** Histopathology showing orthokeratosis, mild acanthosis, and basal cell vacuolar degeneration. Mild lichenoid lymphocytic infiltrate in the interface is noted. Superficial and deep dermis shows parallelly arranged thickened collagen bundles and mild lymphocytic perivascular inflammation with melanophages (H & E, 100x).