



Off-Label Use of Upadacitinib for Treatment of Lichen Planus: A Narrative Review

Mark Gregory¹, Negar Esfandiari², Steven Daveluy²

¹ Wayne State University School of Medicine, Detroit, MI, USA

² Dermatology, Wayne State University School of Medicine, Detroit, MI, USA

Key words: Upadacitinib, Janus kinase, JAK inhibitor, Lichen planus, Lichen planopilaris

Citation: Gregory M, Esfandiari N, Daveluy S. Off-Label Use of Upadacitinib for Treatment of Lichen Planus: A Narrative Review. *Dermatol Pract Concept*. 2026;16(2):6449. DOI: <https://doi.org/10.5826/dpc.1602a6449>

Accepted: March 9, 2025; **Published:** April 2026

Copyright: ©2026 Gregory et al. This is an open-access article distributed under the terms of the Creative Commons Attribution-NonCommercial License (BY-NC-4.0), <https://creativecommons.org/licenses/by-nc/4.0/>, which permits unrestricted noncommercial. use, distribution, and reproduction in any medium, provided the original. authors and source are credited.

Funding: None.

Competing Interests: Steven Daveluy – speaker, researcher, and consultant for Abbvie; Mark Gregory and Negar Esfandiari do not have any competing interests to declare.

Authorship: All authors have contributed significantly to this publication.

Corresponding Author: Mark Gregory, Dermatology, Wayne State University School of Medicine, 540 E. Canfield Ave. Detroit, MI 48201. ORCID: 0000-0003-3367-7539. E-mail: markgregory@wayne.edu

ABSTRACT Introduction: Lichen planus (LP) is a chronic inflammatory disorder that primarily affects middle-aged adults and can involve the skin (cutaneous LP), mucous membranes (oral, esophageal, ocular, or vulvar LP), hair (lichen planopilaris, LPP), and nails. The exact cause of LP is not known, but the pathogenesis is thought to be multifactorial and involves T-cell mediated attack of skin and mucous membranes.

Objectives: The purpose of this review was to summarize the available reports regarding treatment of LP with the selective and reversible Janus kinase (JAK) 1 inhibitor upadacitinib.

Methods: PubMed and Google Scholar databases were queried using LP and upadacitinib terms with Boolean operators and assessed using the Oxford evidence criteria.

Results: Sixteen reports were included, comprising a 27 total of patients (19 females and eight males). Most cases were cutaneous LP (N=14, 51.8%) and LPP (N=6, 22.2%). Prior treatments included topical corticosteroids (N=21, 77.8%) and disease-modifying antirheumatic drugs (DMARDs) (N=14, 51.9%). The most common upadacitinib dosages were 15 mg once daily (N=19, 70.4%) and 30 mg once daily (N=5, 18.5%). Most patients achieved remission (N=21, 77.8%) after a median one month which lasted a median three months after treatment cessation or five months in patients who continued to receive treatment. Upadacitinib therapy had minimal, self-limited side effects (N=4, 14.8%).

Conclusions: Upadacitinib demonstrates potential as a tolerable and effective off-label treatment for LP. Larger studies are warranted to better define the safety and efficacy of upadacitinib in treating LP.

Introduction

Lichen planus (LP) is a chronic inflammatory disorder that primarily affects middle-aged adults and can involve the skin (cutaneous LP), mucous membranes (oral, esophageal, ocular, or vulvar LP), hair (lichen planopilaris, LPP), and nails. The exact cause of LP is not known; however, the pathogenesis is believed to be multifactorial. LP and its variants have been shown to be genetically associated with polymorphisms in human leukocyte antigen (HLA) alleles [1] as well as with tumor necrosis factor (TNF), interferon gamma (IFN- γ), and other proinflammatory cytokines [2]. In addition to genetics, chronic infection with hepatitis C virus [3] and human herpes virus 7 [4] as well as dysregulation of dendritic cells [5] have been observed in oral and cutaneous LP. Beyond viral infection and immune cell dysregulation, oral LP and LPP have been linked to neurogenic inflammation evidenced by intralesional imbalances of neuropeptide neurokinin 1 receptor, substance P [6] and calcitonin gene-related peptide [7]. Moreover, vulvar LP has been shown to be associated with circulating and epidermal autoreactive antibodies to bullous pemphigoid antigens 180 and 230 [8,9] and other autoimmune diseases [10], suggesting a secondary link to autoimmunity. Additionally, medications have been implicated in triggering cutaneous lichenoid drug eruptions that can mimic LP. These medications include angiotensin-converting enzyme inhibitors, thiazide diuretics, checkpoint inhibitors, anti-inflammatory drugs, antimalarials, antimicrobials, antihypertensives, antidiabetics, and psychiatric drugs [1]. Lichenoid eruptions are thought to be driven by CD8+ T cell-driven attack against drug-induced hapten stimuli on epidermal keratinocytes.

LP can be treated with phototherapy, topical and intralesional corticosteroids, phosphodiesterase-4 (PDE4) inhibitors, TNF- α inhibitors, and Janus kinase (JAK) inhibitors. JAK1 mediates IFN- γ signaling, and IFN- γ -induced chemokine ligands 9 and 10 have been found to be highly expressed in the serum, skin and mucosal lesions in patients with LP [11]. Thus, targeting JAK1 has been proposed as a treatment strategy to alleviate the excessive IFN- γ activity seen in the pathogenesis of LP [11]. The purpose of this narrative review was to summarize the use of the selective and reversible JAK1 inhibitor upadacitinib as a potential effective treatment option for patients with LP unresponsive to conventional therapies.

Objectives

We aimed to synthesize the published literature reporting the use of upadacitinib for the treatment of LP.

Methods

To synthesize this narrative review, we searched PubMed and Google Scholar for reports for LP treated with upadacitinib. The search terms included: lichen planus, cutaneous lichen planus, mucosal lichen planus, oral lichen planus, lichenoid, lichen planopilaris, janus kinase, and upadacitinib. To ensure a comprehensive search, we also employed Boolean operators, including but not limited to: “lichen planus AND upadacitinib”, “lichen planus AND Janus kinase”, “lichen planus AND upadacitinib OR Janus kinase”, “lichenoid AND upadacitinib,” and so on. The inclusion criteria for this narrative review were peer-reviewed cases or case series published in the last 25 years involving LP and its variants or lichenoid eruptions treated with upadacitinib. The exclusion criteria included reports unrelated to LP, commentaries, reviews, and non-English publications. Figure 1 depicts the search strategy utilized for this narrative review. Each report was screened for inclusion independently by two members of the research team (M.G. and N.E.) with disagreements resolved by the senior author (S.D.), yielding 16 relevant publications from 2021 to 2025. The included studies were assessed for quality of evidence using criteria established from the 2009 Oxford Centre for Evidence Based Medicine Levels of Evidence (Table 1).

Results

Nineteen female (70.4%) and eight male (29.6%) patients diagnosed with LP and its variants or lichenoid eruptions were treated with upadacitinib (Table 2). Of the 16 reports, two included 10- and 14-year-old children (<18 years) and the rest were adults (\geq 18 years). LP diagnoses included cutaneous LP (13/27), LPP (7/27), esophageal LP (3/27), oral LP (2/27), LP pemphigoides (1/27), and one lichenoid drug eruption (Table 2). Prior LP treatments included topical corticosteroids (21/27), disease-modifying antirheumatic drugs (DMARDs) such as methotrexate and hydroxychloroquine (14/27), intralesional corticosteroids (10/27), oral corticosteroids (9/27), oral retinoids (6/27), systemic corticosteroids (3/27), ultraviolet B phototherapy (2/27), and various therapies utilized in individual patients (ultraviolet A phototherapy, psoralen plus ultraviolet A phototherapy, intramuscular corticosteroids, glycyrrhizin and glucosides) [12] (Table 2). Upadacitinib was administered orally with the following three treatment regimens: i) 15 mg daily (19/27); ii) 30 mg daily (5/27); iii) 30 mg daily for two weeks then 15 mg daily (3/27) (Table 2). The rationale for treating with upadacitinib 30 mg daily for two weeks and then 15 mg daily in three LP patients was not provided by the authors [13].

Upadacitinib was well tolerated with most patients, demonstrating no side effects (23/27); two other patients

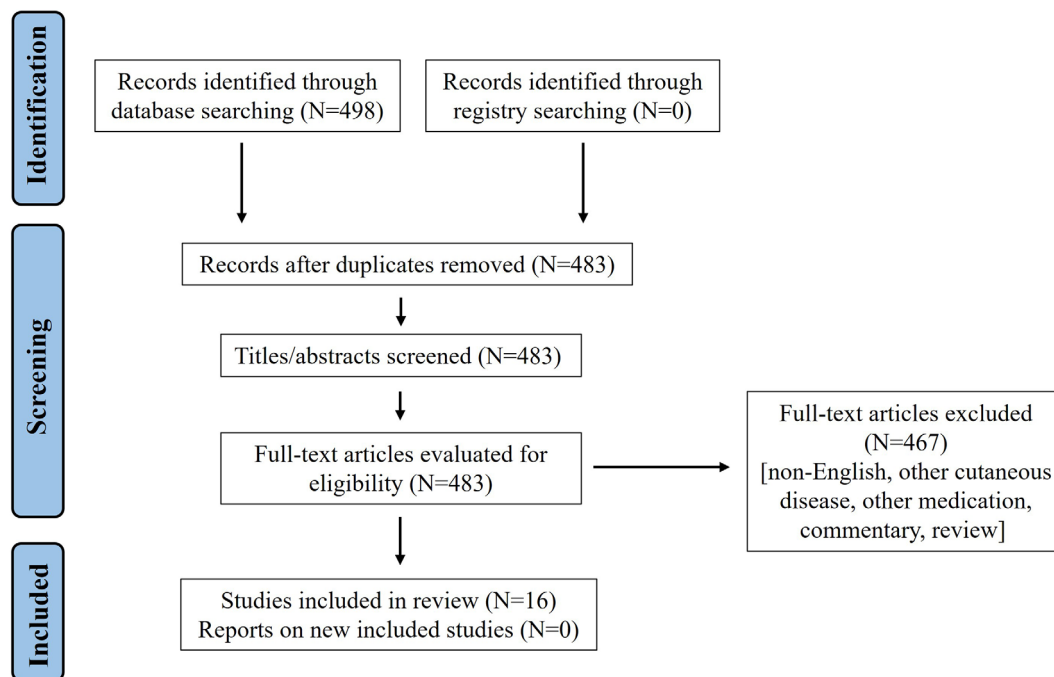


Figure 1. Flow Diagram of Research Strategy Based on Preferred Reporting Items for Systematic Reviews and Meta-Analyses 2020.

Table 1. Quality of evidence as determined by the 2009 Oxford Centre for Evidence-Based Medicine.

Author	Publication Year	Level of Evidence
Balestri et al. [17]	2022	4
Becker et al. [23]	2023	4
Böll et al. [24]	2024	4
Gueissaz et al. [18]	2024	4
Kooybaran et al. [20]	2021	4
Landells et al. [26]	2023	4
Lasheras-Pérez et al. [15]	2024	4
McNamara et al. [13]	2025	4
Politou et al. [14]	2024	4
Rosenbaum et al. [27]	2024	4
Schundler et al. [21]	2025	4
Sheehan et al. [22]	2025	4
Xia et al. [16]	2025	4
Ying et al. [19]	2024	4
Yu et al. [12]	2024	4
Zundell et al. [25]	2023	4

reported mild acne, two with transient liver enzymes elevation, and one with mild headache and worsening of a pre-existing herpes simplex virus infection (Table 2). Remission was achieved in 21/27 patients, with time to remission from one to 24 weeks after upadacitinib treatment, with a median

of four weeks (Table 2). Twelve patients with cutaneous LP experienced remission after one to 36 months (Table 2). One patient who was diagnosed with LP pigmentosus, a rare variant of cutaneous LP, demonstrated remission after four months [13]. In the seven LPP patients, upadacitinib led to remission after six months in one patient [13], 1.5 months in another patient [14], and hair regrowth after seven months in a case series of five patients [15]. All three esophageal LP and two oral LP patients demonstrated remission after one week to three months (Table 2). One patient previously managed with ustekinumab for psoriasis developed a lichenoid drug eruption that was treated with upadacitinib, which led to remission after one month [16]. In the 21 patients who did achieve remission with upadacitinib, remission lasted for at least 1–6 months after treatment cessation (four patients, median three months) [16–19] and at least 1–36 months while still receiving treatment (seven patients, median five months) [12–14,20–22]. For 10 patients, remission duration was not reported (Table 2).

Upadacitinib therapy was maintained in 17/21 patients [13–15,17,20–25]. In four patients, upadacitinib was suspended [16–19]. Xia et al. reported a case of a patient with LP that completely responded to upadacitinib 15 mg daily which prompted independent treatment discontinuation [16]. One month later, scattered scaly plaques developed on the back and scalp, accompanied by minimal pruritus that gradually resolved with topical corticosteroids [16]. In a case of lichen planus pemphigoides that resolved with upadacitinib 15 mg daily, five months after therapy cessation,

Table 2. Upadacitinib for the treatment of LP and variants.

Author	Age, Sex	Dx	Prior LP treatment	UPA dose*	Side effects	UPA time to/duration of LP remission
Balestri [17]	45F	OLP	NR	15 mg	NR	1 wk. / >12 wk.
Becker [23]	68F	ELP	O CS	30 mg	NR	3 mo. / NR
Böll [24]	26F, 43M, 25F, 56 F, 35 F	CLP	IM, T CS, UVB, UVA, P-UVA, OR	15 mg	NR	Days (3)***, weeks (2) / NR (5)
Gueissaz [18]	56F	LPPG	T CS	15 mg	NR	Days / > 6 mo.
Kooybaran [20]	59F	ELP	T CS	15 mg	NR	1 mo. > 5 mo.
Landells [26]	70F	ELP	IV CS, DM ARDs, OR	15 mg	NR	Remission time NR / NR
Lasheras-Pérez [15]	14M, 51F, 50M, 30F, 42F	LPP	T, IL, O CS, DMARDs, OR	15 mg (1), 30 mg (4)	Acne (2), LFTE (1), NR (2)	LP remission not achieved; hair regrowth after 7 months of UPA
McNamara [13]	50M, 20F, 60F, 40F	CLP (3), LPP (1)	T, IL CS, DMARDs	30 (2 wk) then 15 mg (3), 15 mg (1)	NR	6 mo. (1), 5 mo. (1), 4 mo. (2) / > 7 mo. (1), > 5 mo. (1), NR (2)
Politou [14]	55F	LPP	T, IV CS	15 mg	NR	1.5 mo. / > 3.5 mo
Rosenbaum [27]	48F	CLP	O CS, DMARDs	15 mg	NR	6 mo. / NR
Schundler [21]	60M	CLP	O, T, IL, IV CS, UV-B, DMARDs	15 mg	NR	3 mo. / > 9 mo.
Sheehan [22]	39F	OLP	O CS	15 mg	HSV	1 mo. / > 3 mo.
Xia [16]	69M	LE	No LP	15 mg	NR	1 mo. / > 3 mo.
Ying [19]	58M	CLP	T CS, DMARDs	15 mg	NR	6 mo. / > 1 mo.
Yu [12]	10M	CLP	T CS	15 mg	LFTE	2 mo. / > 36 mo.
Zundell [25]	46F	CLP	T CS, DMARDs	15 mg	NR	Lesion healing after 6 weeks of LP treatment

Abbreviations: LP: lichen planus, OLP / ELP / CLP: oral / esophageal / cutaneous LP, LPP: lichen planopilaris, LPPG: lichen planus pemphigoides, LE: lichenoid eruption, T: topical, O: oral, IM: intramuscular, IV: intravenous, IL: intralesional, CS: corticosteroids, OR: oral retinoids, DMARDs: disease-modifying antirheumatic drugs, UVA/UVB: ultraviolet A/B, P-UVA: psoralen plus ultraviolet A, HSV: herpes simplex virus, LFTE: liver function test elevation, NR: none reported, UPA: upadacitinib, wk.: week(s), mo.: month(s); *UPA administered once daily in all reports; ***(X): X patients

excoriations were noted on the lower extremities which were managed with topical. clobetasol twice weekly [18]. Ying et al. reported on a patient with cutaneous LP that resolved with upadacitinib 15 mg daily and remained free of recurrence for one month after treatment cessation, with no further reported follow-up [19]. In a similar case, improvement of esophageal LP with upadacitinib 15 mg daily prompted treatment discontinuation, with no observed relapses over an unspecified follow-up time [26]. A case of cutaneous LP that resolved with upadacitinib 15 mg daily prompted an attempt to switch dosing from every day to every other day for one month, which led to worsening of pruritus [27]. Switching the frequency of upadacitinib back to daily dosing led to pruritus control [27].

Per the authors' reports, 18/21 patients did not have risk factors that would raise concern for use of upadacitinib [12-21,23,25-27]. In three patients, pre-existing risk factors warranted caution with upadacitinib therapy [22,24]. A patient with a past medical. history of recurrent herpes simplex virus infection presented with oral. LP that demonstrated complete response to upadacitinib 15 mg daily [22]. During therapy, the pre-existing viral. infection worsened, which prompted administration of valacyclovir 500 mg daily and continuation of upadacitinib, leading to resolution of the infection while maintaining LP remission [22]. Böll et al. reported two patients with elevated lipid levels before therapy with upadacitinib 15 mg daily that did not increase during treatment [24].

Discussion

LP is thought to involve T-cell-mediated attack of the epithelia of the skin and mucous membranes [1]. Since JAKs are involved in IFN- γ signaling that is crucial to T-cell function, they may serve as actionable targets for LP treatment. Several JAK inhibitors with various selectivities for the JAK enzymes have been reported to be safe and efficacious in treating LP. These include tofacitinib (JAK1/3 inhibitor), baricitinib (JAK1/2 inhibitor), ruxolitinib (JAK1/2 inhibitor) [1], and upadacitinib, a JAK1 inhibitor, presented in this review.

Conventional treatments for LP often include topical corticosteroids as a first-line therapy, with systemic corticosteroids, phototherapy, retinoids, immunosuppressants such as cyclosporine, or DMARDs such as methotrexate reserved for more severe or widespread disease. Historically, these therapeutic approaches have primarily aimed to control symptoms rather than achieve durable resolution. However, emerging therapies, including targeted immunomodulators and biologics, show promising potential to improve the quality of life and lead to sustained remission in patients with refractory LP.

In the reports included herein where upadacitinib was used to treat LP, 77.8% and 51.9% of patients initially received topical corticosteroids and DMARDs, respectively. While corticosteroids, other immunosuppressives, and DMARDs agents are standard therapies for LP, they often alleviate symptoms temporarily and may have an unfavorable side effect profile. Our review highlights the emerging role of upadacitinib, a JAK1 inhibitor, in the management of LP and its variants, including cutaneous, oral, and esophageal LP, and LPP as well as lichenoid drug eruption. In our review, several small case series and reports show that LP patients treated with upadacitinib experienced clinical improvement (22.2%) or complete remission (77.7%), indicating a durable response with few transient side effects (14.8%).

Limitations of this review include a lack of standardized reporting among different manuscripts, the current evidence being restricted to case reports and series, and possible exclusion of articles relevant to this report due to the search strategy.

Conclusion

Upadacitinib shows promise as an effective and tolerable off-label treatment for LP, especially in patients who failed to respond to immunosuppressive therapies. Clinically significant improvement or stable remission was achieved in all reported cases, with few side effects. Larger patient cohorts and further prospective studies are needed to better delineate the safety and efficacy of upadacitinib in treating LP.

References

1. Boch K, Langan EA, Kridin K, Zillikens D, Ludwig RJ, Bieber K. Lichen Planus. *Front Med*. 2021;8. DOI:10.3389/fmed.2021.737813.
2. Gorouhi F, Davari P, Fazel N. Cutaneous and Mucosal. Lichen Planus: A Comprehensive Review of Clinical. Subtypes, Risk Factors, Diagnosis, and Prognosis. *ScientificWorldJournal*. 2014; 2014:742826. DOI:10.1155/2014/742826.
3. Pilli M, Penna A, Zerbini A, et al. Oral. lichen planus pathogenesis: A role for the HCV-specific cellular immune response. *Hepatology*. 2002;36(6):1446. DOI:10.1002/hep.1840360622.
4. de Vries HJC, Teunissen MBM, Zorgdrager F, Picavet D, Cornelissen M. Lichen planus remission is associated with a decrease of human herpes virus type 7 protein expression in plasmacytoid dendritic cells. *Arch Dermatol Res*. 2007;299(4):213-219. DOI:10.1007/s00403-007-0750-0.
5. Wang Y, Shang S, Sun Q, et al. Increased infiltration of CD11c+ / CD123+ dendritic cell subsets and upregulation of TLR/IFN- α signaling participate in pathogenesis of oral lichen planus. *Oral Surg Oral Med Oral Pathol Oral Radiol*. 2018;125(5):459-467. e2. DOI:10.1016/j.oooo.2017.12.003.
6. González Moles M, Esteban F, Ruiz-Ávila I, et al. A role for the substance P/NK-1 receptor complex in cell proliferation and apoptosis in oral lichen planus. *Oral Diseases*. 2009;15(2): 162-169. DOI:10.1111/j.1601-0825.2008.01504.x.
7. Doche I, Wilcox GL, Ericson M, et al. Evidence for neurogenic inflammation in lichen planopilaris and frontal. fibrosing alopecia pathogenic mechanism. *Experimental. Dermatology*. 2020; 29(3):282-285. DOI:10.1111/exd.13835.
8. Cooper SM, Dean D, Allen J, Kirtschig G, Wojnarowska F. Erosive lichen planus of the vulva: weak circulating basement membrane zone antibodies are present. *Clin Exp Dermatol*. 2005;30(5):551-556. DOI:10.1111/j.1365-2230.2005.01866.x.
9. Howard A, Dean D, Cooper S, Kirtschig G, Wojnarowska F. Circulating basement membrane zone antibodies are found in lichen sclerosis of the vulva. *Australas J Dermatol*. 2004;45(1):12-15. DOI:10.1111/j.1440-0960.2004.00026.x.
10. Cooper SM, Ali I, Baldo M, Wojnarowska F. The Association of Lichen Sclerosis and Erosive Lichen Planus of the Vulva With Autoimmune Disease: A Case-Control Study. *Archives of Dermatology*. 2008;144(11):1432-1435. DOI:10.1001/archderm.144.11.1432.
11. Di Lernia V. Targeting the IFN- γ /CXCL10 pathway in lichen planus. *Med Hypotheses*. 2016;92:60-61. DOI:10.1016/j.mehy.2016.04.042.
12. Yu F, Wu W, Chen S, Yang B. Successful treatment of childhood lichen planus with upadacitinib. *Postepy Dermatol Alergol*. 2024; 41(1):139-141. DOI:10.5114/ada.2023.135616.
13. McNamara ME, Tjahjono L. Successful treatment of recalcitrant cutaneous lichen planus and unusual variants with upadacitinib: A case series and a literature review of systemic Janus kinase inhibitors use in cutaneous lichen planus and lichen planopilaris. *JAAD Case Reports*. 2025;59:147-154. DOI:10.1016/j.jcder.2025.01.014
14. Politou M, Almpanis Z, Fekkas N. 52231 Upadacitinib for the treatment of recalcitrant lichen planopilaris: First case reported. *Journal of the American Academy of Dermatology*. 2024;91(3):AB95. DOI:10.1016/j.jaad.2024.07.384.

15. Lasheras-Pérez MA, Palacios-Díaz RD, Pujol-Marco C, Escutia-Muñoz B, Botella-Estrada R. Recalcitrant lichen planopilaris treated with upadacitinib: a case series. *Int J Dermatol*. 2024;63(12):1802-1804. DOI:10.1111/ijd.17339.
16. Xia M, Zhang J, Tian X, Chen Z, Liang J, Liu Y. Successful Treatment of Ustekinumab-Associated Lichenoid Drug Eruption with Upadacitinib: A Case Report. *Clin Cosmet Investig Dermatol*. 2025;18:801-804. DOI:10.2147/CCID.S513281.
17. Balestri R, Bortolotti R, Rech G, Girardelli CR, Zorzi MG, Magnano M. Treatment of Oral Erosive Lichen Planus With Upadacitinib. *JAMA Dermatol*. 2022;158(4):457-458. DOI:10.1001/jamadermatol.2022.0147
18. Gueissaz L, Wolf R, Schlapbach C. Rapid and Sustained Improvement of Lichen Planus Pemphigoides With the JAK1 Inhibitor Upadacitinib. *JEADV Clinical Practice*. Published online December 18, 2024;jvc2.603. DOI:10.1002/jvc2.603.
19. Ying Y, Jia-Min H, Zhao-Jun S. Treating Inverse Lichen Planus With Upadacitinib: A Case Study. *Australas J Dermatol*. 2025;66(3):e182-e184. DOI:10.1111/ajd.14459.
20. Kooybaran NR, Petzold G, Ströbel P, Schön MP, Mössner R. Alleviation of erosive oral and esophageal lichen planus by the JAK1 inhibitor upadacitinib. *J Dtsch Dermatol Ges*. 2021; 19(12):1778-1780. DOI:10.1111/ddg.14612.
21. Schundler SF, Noot CH, Frost Z, Clarke J, Hopkins ZH. Treatment of recalcitrant hypertrophic lichen planus with upadacitinib. *JAAD Case Rep*. 2025;59:78-80. DOI:10.1016/j.jdc.2025.02.029.
22. Sheehan CA, Brownstone ND, Lee JB, Hsu S. Successful Use of Upadacitinib for Recalcitrant Oral Erosive Lichen Planus. *JAAD Case Reports*. Published online March 2025;S2352512625001158. DOI:10.1016/j.jdc.2025.02.042.
23. Becker EC, Mavilia-Scranton M, Finch J, Yu M, Rezaizadeh H. Use of Upadacitinib in Refractory Esophageal Lichen Planus: Endoscopic Improvement in “Planus” Sight. *ACG Case Rep J*. 2023;10(11):e01200. DOI:10.14309/crj.0000000000001200.
24. Böll SL, Zahn CA, Schlapbach C. Rapid and sustained improvement of cutaneous lichen planus with oral JAK1 inhibitors. *J Eur Acad Dermatol Venereol*. 2024;38(1):e82-e85. DOI:10.1111/jdv.19440.
25. Zundell MP, Kaminetsky J, Lebwohl M, Gottlieb AB. Successful Treatment of Lichen Planus With Oral Upadacitinib. *J Drugs Dermatol*. 2023;22(10):1058-1060. DOI:10.36849/JDD.7272.
26. Landells FM, Goudie S, McGrath J, Tibbo J, Landells ID. Successful treatment of erosive lichen planus with Upadacitinib complicated by oral squamous cell carcinoma. *SAGE Open Med Case Rep*. 2023;11:2050313X231213144. DOI:10.1177/2050313X231213144.
27. Rosenbaum C, Tan VT, Grekin JA, Fulton E, Treyger G. Unilateral blaschkoid lichen planus successfully treated with upadacitinib. *JAAD Case Rep*. 2024;45:35-37. DOI:10.1016/j.jdc.2024.01.007.