

A Comprehensive Evaluation of the Efficacy of Intense Pulsed Light and Neodymium-doped Yttrium Aluminum Garnet Laser Treatments in Nail Psoriasis

Merve Aygün Alizada¹, Seher Bostancı¹, Mehmet Fatih Atak², Banu Farabi²,
Bengü Nisa Akay¹

¹ Department of Dermatology, Faculty of Medicine, Ankara University, Ankara, Turkey

² Department of Dermatology, New York Medical College, New York, USA

Key words: Nail psoriasis, IPL, Nd:YAG laser

Citation: Alizada MA, Bostancı S, Atak MF, Farabi B, Akay BN. A Comprehensive Evaluation of the Efficacy of Intense Pulsed Light and Neodymium-doped Yttrium Aluminum Garnet Laser Treatments in Nail Psoriasis. *Dermatol Pract Concept.* 2026;16(2):6551. DOI: <https://doi.org/10.5826/dpc.1602a6551>

Accepted: December 24, 2025; **Published:** April 2026

Copyright: ©2026 Alizada et al. This is an open-access article distributed under the terms of the Creative Commons Attribution-NonCommercial License (BY-NC-4.0), <https://creativecommons.org/licenses/by-nc/4.0/>, which permits unrestricted noncommercial use, distribution, and reproduction in any medium, provided the original authors and source are credited.

Funding: None.

Competing Interests: None.

Authorship: All authors have contributed significantly to this publication.

Corresponding Author: Merve Aygün Alizada, MD Ankara University Faculty of Medicine, Department of Dermatology, Talatpasa 06320Altındag, Ankara, Turkey. ORCID: 0000-0003-2732-9132. E-mail: werve2007@gmail.com

ABSTRACT Introduction: Nail psoriasis significantly impairs quality of life and remains therapeutically challenging due to the limited efficacy of treatments.

Objectives: To compare the clinical efficacy and safety of Nd:YAG laser and intense pulsed light (IPL) therapy in nail psoriasis using total and modified NAPSI scores, clinical and dermatoscopic findings.

Methods: This retrospective study evaluated 101 nails from 14 patients treated with either IPL (N=66) or Nd:YAG laser (N=35). Treatments were administered every 4–6 weeks for 2–8 sessions. Nail psoriasis severity was assessed at baseline and at six months using NAPSI, mNAPSI, and dermatoscopic and clinical features.

Results: PL therapy significantly reduced matrix (3.48→1.94), nail bed (3.47→1.33), total NAPSI (6.95→3.27), and mNAPSI (9.21→3.92) scores ($P<0.05$). Nd:YAG laser treatment also resulted in significant improvements in matrix (3.54→2.20), nail bed (3.77→1.97), total NAPSI (7.31→4.17), and mNAPSI (8.83→5.23) scores ($P<0.05$). In our cohort, IPL appeared to have a more favorable impact on mNAPSI, pitting, salmon patches, subungual hyperkeratosis, and splinter hemorrhages, while Nd:YAG tended to provide greater improvement in leukonychia ($P<0.05$). No recurrence or adverse event was observed during the 12-month follow-up period.

Conclusions: Both IPL and Nd:YAG laser therapies are safe and effective options for nail psoriasis. IPL showed superior efficacy in nail bed involvement, whereas Nd:YAG may be preferred for leukonychia. Laser-based treatments are promising alternatives in refractory cases.

Introduction

Psoriasis is a chronic inflammatory skin disease, with approximately 2550% of patients having nail involvement. Nail involvement is a risk factor for the development of psoriatic arthritis, and the frequency of nail psoriasis in PSA patients is 70% [1, 2]. Since fingernails are frequently affected and this unacceptable nail appearance is accompanied by pain in 50% of patients, quality of life is significantly negatively affected [1, 2]. In fact, the Nail Psoriasis Severity Index (NAPSI) and Dermatological Life Quality Index have been found to be correlated in studies [3]. Nail findings vary according to the pathologically involved area of the nail. Pitting, leukonychia, red spot in the lunula, and nail plate crumbling are seen in matrix involvement, while oil drop discolorations-salmon patch, onycholysis, hyperkeratosis, and splinter hemorrhage are seen in nail bed involvement [1]. Nail psoriasis is more severe in patients with early onset of the disease and in the presence of a family history [2].

The management of nail psoriasis poses a considerable challenge, necessitating a patient-specific approach tailored to the severity of the condition [2]. This complexity arises from the limited efficacy and discomfort associated with topical therapies as well as from the potential for systemic adverse effects associated with systemic treatment options [2].

Recent studies have demonstrated the efficacy of light and laser-based treatments such as phototherapy, intense pulsed light (IPL) and pulsed dye laser (PDL), and 1064 nm neodymium-doped yttrium aluminum garnet (Nd:YAG) laser as effective treatment options for nail psoriasis [4, 5].

Objectives

This study aimed to provide the first comparative evaluation in the literature of Nd:YAG laser versus IPL therapy in the treatment of nail psoriasis.

Methods

A total of 101 nails (92 fingernails and nine toenails) from 14 patients with nail psoriasis who received Nd:YAG laser or IPL treatment at the Dermatology Department of Ankara University School of Medicine between 2016 and 2023 were evaluated. The study was approved by the Ethics Committee of Ankara University (Approval No: 2024/559). Informed consent was obtained from all participants.

The diagnosis of nail psoriasis was made on the basis of clinical, dermatoscopic, and pathological examinations. A total of ten patients exhibited cutaneous manifestations, while four patients presented with isolated instances of nail psoriasis. Patients diagnosed with onychomycosis, as

determined by evaluation with native preparation and fungal culture, and patients diagnosed with pustular psoriasis were excluded from the study. Patients who had received systemic or topical psoriasis treatments within six months before or after the study treatment period were excluded. Furthermore, patients suffering from coagulation disorders, hypertrophic scars, or a history of keloid formation were not included in the study.

Of the 14 patients included in the study, nine received IPL treatment applied to 61 fingernails and five toenails (a total of 66 nails). The parameters employed for IPL treatment consisted in a pulse duration of 5 ms, a spot size of 4×1 cm, a pulse delay of 5–10 ms, and a fluence of 20 J/cm² (560 handpick). Patients underwent an average of six sessions (4–8 sessions), with 4-week intervals. Five patients received Nd:YAG laser treatment, which was applied to a total of 35 nails, including 31 fingernails and four toenails. The parameters employed for the Nd:YAG treatment consisted in a pulse duration of 15 milliseconds, a spot size of 4 mm, and a fluence of 100 J/cm². The mean number of sessions was 4.8 (range 2–6 sessions), with 4-week intervals. No topical anesthetic was administered to any patient, and pain scores were recorded during the procedure using the visual analogue scale (VAS).

Prior to treatment and at the six-month follow-up, the severity of nail psoriasis was assessed using the following metrics: nail bed, nail matrix, and total NAPSI scores (8 points) as well as the modified NAPSI score. The following clinical findings were also considered: onycholysis, pitting, red spots on the lunula, salmon patches, leukonychia, splinter hemorrhages, and hyperkeratosis. A series of clinical and dermatoscopic photographs were taken, and patients were observed for signs of recurrence for an average period of 12 months (range 6–18 months).

Statistical analyses were performed using SPSS software (version 27; IBM Corp., Armonk, NY, USA). Descriptive statistics are presented as frequencies and percentages for categorical variables, and as mean ± standard deviation (SD) or median with interquartile range (IQR) for continuous variables, as appropriate. The Shapiro–Wilk test was used to evaluate the normality assumption for continuous variables.

Since the distributions of the continuous variables deviated from normality, non-parametric statistical tests were employed. Between-group comparisons were conducted using the Mann–Whitney U test, while within-group pre-to-post-treatment comparisons were analyzed using the Wilcoxon signed-rank test. For paired categorical variables, McNemar's test was applied. Associations between independent categorical variables were assessed using Pearson's chi-square test.

A two-tailed p-value of <0.05 was considered statistically significant for all analyses.

Results

Fourteen patients (10 females, four males) were evaluated. The mean age was 28.6 years (range: 8–58 years), and the mean disease duration was nine years (range: 1–20 years). Baseline PASI, NAPS, and mNAPS scores and the rate of cutaneous involvement were similar between the IPL and Nd:YAG groups ($P>0.05$). Detailed patient information is presented in Table 1.

In the overall cohort, the mean matrix score decreased from 3.5 prior to treatment to 2.03 at the six-month follow-up. At the same time, the bed score declined from 3.57 to 1.55. The total NAPS score decreased from 7.08 to 3.58, while the modified NAPS score fell from 9.08 to 4.38. Pretreatment findings included onycholysis in 77 nails, pitting in 94 nails, red spots on the lunula in 74 nails, salmon patches in 52 nails, leukonychia in 91 nails, and hyperkeratosis in 74 nails. At the six-month follow-up, onycholysis was present in 39 nails, pitting in 87 nails, red spots in 27 nails, salmon patches in 23 nails, leukonychia in 74 nails, and hyperkeratosis in 32 nails.

In the IPL-treated group ($N=66$), matrix scores decreased from 3.48 to 1.94, bed scores from 3.47 to 1.33, total NAPS scores from 6.95 to 3.27, and modified NAPS scores from 9.21 to 3.92 ($P<0.05$). Pretreatment onycholysis was observed in 56 nails, while posttreatment onycholysis was observed in 26 nails ($P<0.05$). Pitting was observed in 64 nails before treatment and 52 nails after treatment (with a pitting score of $P<0.05$). Prior to treatment, red spots were present on 47 nails; after treatment, this number decreased to 13 ($P<0.05$). The number of salmon patches decreased from 36 to seven ($P<0.05$). Leukonychia was observed in 56 nails before treatment and 52 nails after treatment ($P>0.05$). Hyperkeratosis decreased from 52 to 10 nails following treatment ($P<0.05$). Splinter hemorrhages were present in 64 nails before treatment and 52 nails after treatment ($P<0.05$) (Table 2A-B, Figures 1, 2).

In the Nd:YAG-treated group ($N=35$), matrix scores decreased from 3.54 to 2.20, bed scores from 3.77 to 1.97, total NAPS scores from 7.31 to 4.17, and modified NAPS scores from 8.83 to 5.23 ($P<0.05$). Pretreatment onycholysis was observed in 21 nails, while posttreatment onycholysis was observed in 13 nails ($P<0.05$). Although pitting was detected

in 30 nails at baseline and 35 nails after treatment, its severity significantly decreased following therapy ($P<0.05$). Red spots were observed on 27 nails prior to treatment and 14 nails following treatment ($p<0.05$). Salmon patches were observed on 16 nails prior to and following treatment. Leukonychia was evident in all 35 nails prior to treatment and in 22 nails following treatment ($P<0.05$). Hyperkeratosis was evident in 22 nails before and after treatment. Splinter hemorrhages were present in all 35 nails before treatment, and there was no improvement after treatment (Table 2A-B, Figures 1, 2).

A comparison of IPL and Nd:YAG laser treatments revealed that both modalities exhibited comparable efficacy in enhancing bed scores, matrix scores, and total NAPS scores and in reducing clinical manifestations such as onycholysis and red spots ($P>0.05$). However, IPL was found to be more effective than Nd:YAG in improving modified NAPS scores, pitting, splinter hemorrhage, hyperkeratosis, and salmon patches ($P<0.05$). Conversely, Nd:YAG laser treatment demonstrated superior efficacy in reducing leukonychia compared to IPL ($P<0.001$) (Figures 1, 2).

The mean VAS pain score during the procedure was 6 in the Nd:YAG group and 5.8 in the IPL group ($P>0.05$). During the one-year follow-up, no recurrences or treatment-related adverse event was observed in the treated nails. We have clarified that all patients were systematically assessed at months 1, 3, 6, and 12, that no adjunctive therapy was administered during follow-up, and that no patient was lost to follow-up.

Discussion

Nail psoriasis can significantly impair quality of life, both due to its cosmetic impact and to the pain reported in nearly half of affected patients [2, 3]. However, treatment remains challenging. Topical agents inadequately penetrate the nail plate, systemic and biologic therapies have notable adverse-effect risks, and intralesional injections are often poorly tolerated [2]. Light-based and laser therapies have therefore emerged as promising alternatives, offering deeper tissue penetration with minimal systemic effects, particularly for refractory nail involvement, although the supporting evidence remains limited [6].

Table 1. Characteristics of patients receiving IPL and Nd:YAG laser therapy.

Treatment Type	Number of Patients (Male/Female)	Mean Age (min–max, years)	Mean Disease Duration (min-max years)	Cutaneous involvement (n) / *PASI (Median)	**VAS score during treatment (Median-IQR)
IPL	9 (3/6)	27.6 (10–58)	9.3 (4–20)	2 patients / 3	5.8 (4.2–6.8)
Nd:YAG Laser	5 (1/4)	30.4 (8–42)	8.4 (1–14)	1 patient/ 3.2	6 (4–6.3)

Abbreviation: IPL: intense pulsed light; Nd:YAG: neodymium-doped yttrium aluminum garnet. *Abbreviations:* PASI: Psoriasis Area and Severity Index; VAS: visual analog scale. *, **: $p>0.05$ with Mann Whitney U test

Table 2. A: Therapeutic effects of IPL and Nd:YAG lasers on nail psoriasis parameters. B: Therapeutic efficacy of IPL and Nd:YAG lasers on clinical manifestations of nail psoriasis.

A.

Parameter	Treatment	Baseline	Post-treatment	Change	p-value*	p-value**
		Mean±SD Median (IQR)	Mean±SD Median (IQR)	Mean±SD Median (IQR)		
Matrix scores	IPL	3.48±0.5 3(3-4)	1.94±1.19 1(1-3)	1.55±1.08 2(0-2)	<.001	0.210
	Nd:YAG	3.54±0.51 4(3-4)	2.20±0.90 2(2-2)	1.34±0.94 1(1-2)	<.001	
Bed scores	IPL	3.47±0.61 4(3-4)	1.33±1.26 1(0-3)	2.14±1.26 2(1-3)	<.001	0.174
	Nd:YAG	3.77±0.43 4(4-4)	1.97±1.04 2(1-2)	1.80±0.9 2(2-2)	<.001	
Total NAPSII scores	IPL	6.95±1.07 7(6-8)	3.27±2.40 2(1-6)	3.68±2.27 4(1-5)	<.001	0.058
	Nd:YAG	7.31±0.83 8(7-8)	4.14±1.90 4(3-4)	3.14±1.77 3(3-4)	<.001	
Modified NAPSII scores	IPL	9.21±2.41 9(7-12)	3.92±2.06 4(2-5)	5.29±3.45 6(1-9)	<.001	0.001
	Nd:YAG	8.83±1.85 9(8-10)	5.23±1.61 5(4-6)	3.60±2.16 5(2-5)	<.001	
Pitting	IPL	1.82±0.91 2(1-3)	1.09±0.72 1(1-2)	0.73±0.76 1(0-1)	<.001	0.035
	Nd:YAG	1.89±1.11 2(1-3)	1.57±0.78 1(1-2)	0.31±0.72 0(0-1)	<.016	
Onycholysis	IPL	2.05±1.04 2(2-3)	0.61±0.94 0(0-1)	1.44±1.23 1(0-3)	<.001	0.274
	Nd:YAG	1.57±1.36 2(0-3)	0.37±0.49 0(0-1)	1.20±0.99 2(0-2)	<.001	

*:Wilcoxon test, **:Mann-Whitney U test

B.

Parameter	Treatment	Baseline N(%)	Post-treatment N(%)	Change N(%)	p-value**	p-value*
Red spots on the lunula	IPL	47(71.2)	13(19.7)	34(51.5)	<.001	0.168
	Nd:YAG	27(77.1)	14(40.0)	13(37.1)	<.001	
Hyperkeratosis	IPL	52(78.8)	10(15.2)	42(63.6)	<.001	0.001
	Nd:YAG	22(62.9)	22(62.9)	0	1.000	
Salmon patch	IPL	36(54.5)	7(10.6)	29(43.9)	<.001	0.001
	Nd:YAG	16(45.7)	16(45.7)	0	1.000	
Leukonychia	IPL	56(84.8)	52(78.8)	4(6.1)	>.050	0.001
	Nd:YAG	35(100.0)	22(62.9)	13(37.1)	<.001	
Splinter hemorrhage	IPL	64(97.0)	52(78.8)	12(18.2)	<.001	0.007
	Nd:YAG	35(100.0)	35(100.0)	0	1.000	

*: Pearson chi-square, **:MC-Nemar

Microvascular alterations, including increased angiogenesis, vascularity, and capillary tortuosity within the nail bed and matrix, play a key role in nail psoriasis pathogenesis. Vascular-targeting systems such as the 595-nm pulsed

dye laser (PDL) selectively target oxyhemoglobin at the dermoepidermal junction, reducing abnormal vasculature and T-cell-mediated inflammation, with proven efficacy in psoriasis [7, 8]. The 1064-nm Nd:YAG laser also targets

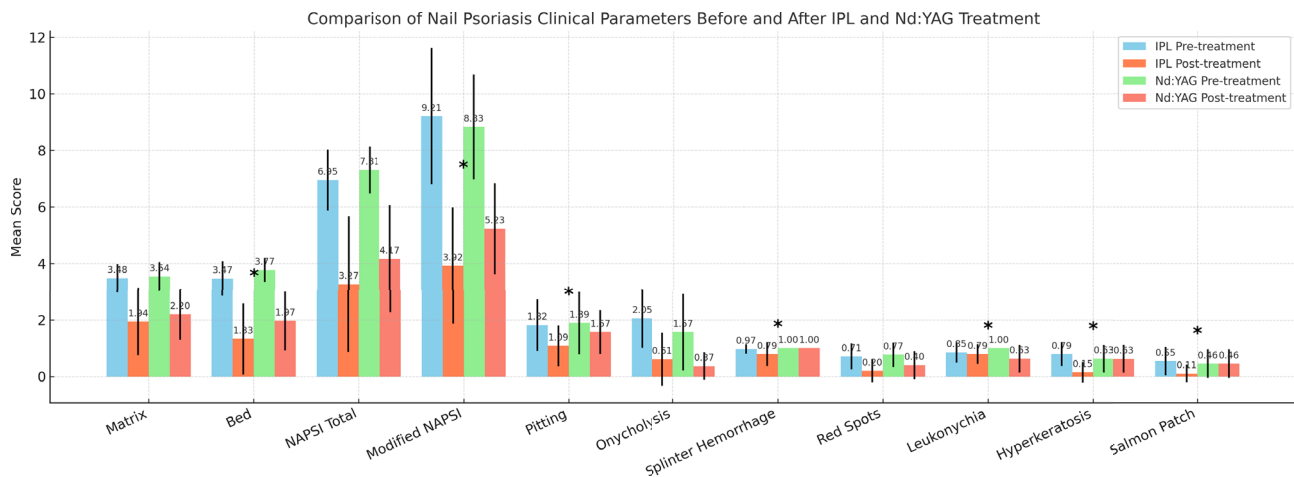


Figure 1. Clinical findings and severity score changes in nail psoriasis treated with IPL and Nd:YAG laser.

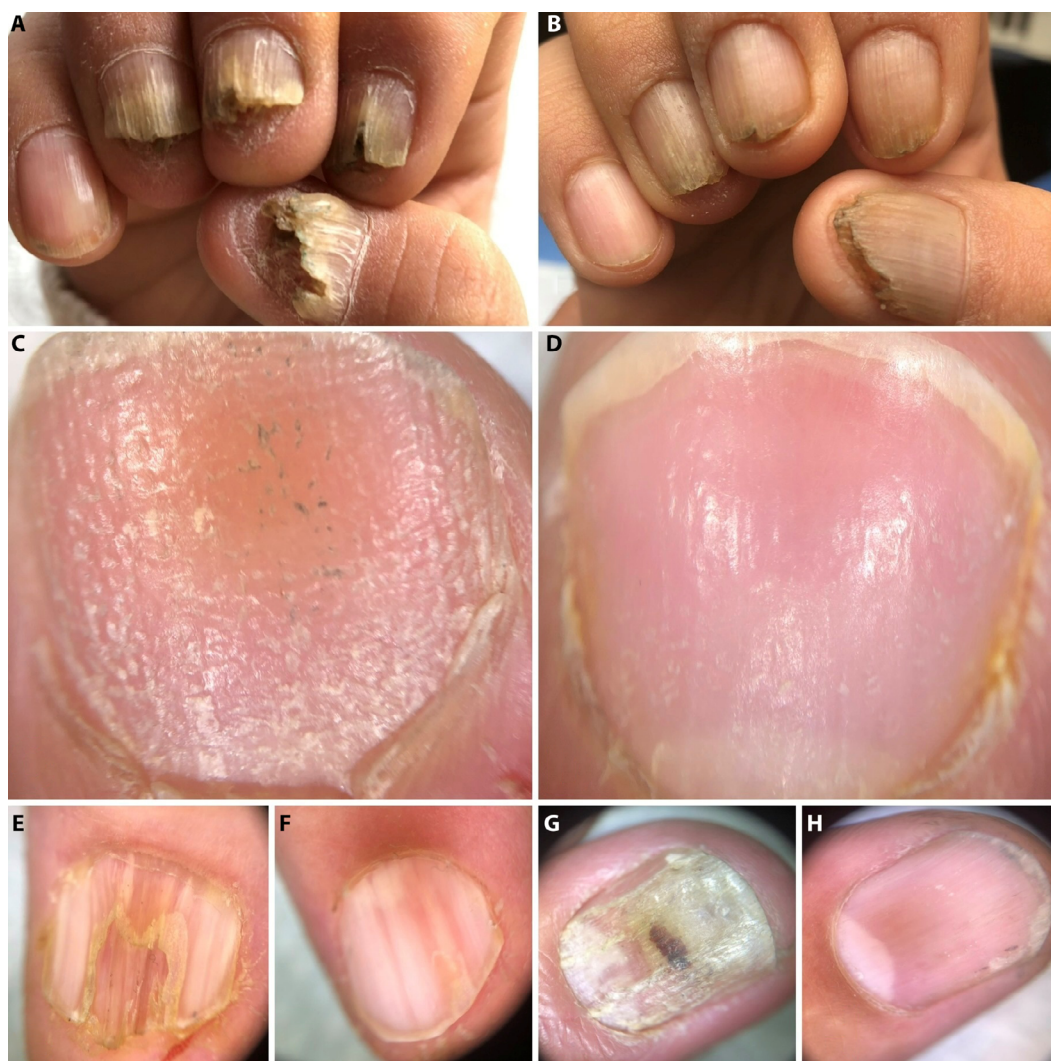

Figure 2. Clinical and dermoscopic improvement of nail psoriasis following laser-based therapies, quantified using the modified Nail Psoriasis Severity Index (mNAPSI). (A, B) Clinical images obtained before (A) and after (B) six sessions of IPL, demonstrating marked regression of onycholysis, crumbling, and subungual hyperkeratosis, with a substantial reduction in mNAPSI score from 18 to 4. (C, D) Dermoscopic images before (C) and after (D) six sessions of Nd:YAG laser, showing a significant decrease in pitting and leukonychia, reflected by a decline in mNAPSI score from 5 to 1. (E, F) Clinical response before (E) and after (F) eight sessions of IPL, with resolution of crumbling, splinter hemorrhages, and oil-drop patches, accompanied by a reduction in mNAPSI score from 7 to 1. (G, H) Clinical images before (G) and after (H) six sessions of IPL, demonstrating improvement in onycholysis, hemorrhage, and discoloration, with a corresponding decrease in mNAPSI score from 7 to 1.

Table 3. Summary of clinical studies evaluating IPL and Nd:YAG laser therapies for nail psoriasis.

Study	Treatment	Session Parameters	Main Outcomes	Adverse Effects-Notes
Tawfik et al. [12]	IPL	Every 2 weeks × 6 months	Significant improvement in matrix (32%), bed (71%) and total NAPSI (82%) (p<0.001)	Mild pain, post-inflammatory hyperpigmentation, 3 recurrences
Morsy / Eman et al. [13]	IPL	Not specified	Significant improvement in matrix (55%) , bed (69%) total and mNAPSI (p<0.05)	Subungual hyperkeratosis: earliest response
Shaheen / Moha et al. [14]	IPL	—	Clinically significant improvement	Well tolerated
Shrook et al. [15]	Nd:YAG (1064 nm)	Monthly • 5 mm • 40 J/cm ²	Significant improvement in matrix (29%), bed (37%) and total NAPSI (33%)	No recurrence
Kartal et al. [16]	Nd:YAG (1064 nm)	Monthly × 12 months	Significant improvement in matrix (77%), bed (86%) and total NAPSI (78%) (p<0.05)	No relapse; excluded severe nail psoriasis
Roter et al. [17]	Nd:YAG vs PDL	—	Both modalities effective and comparable	Confirms Nd:YAG effectiveness
Elwan / Yasmin et al. [18]	Nd:YAG	Facial telangiectasia settings	Only matrix improvement; no bed or total NAPSI	50% toenails → lower penetration depth
El-Basiony et al. [19]	Nd:YAG	—	Improvement target NAPSI and pitting (33%) (p>0,05), Significant reduction in nail bed and matrix thickness and dermal vascularity with USG (p<0,05)	↓ bed/matrix thickness + vascularity

Abbreviations: IPL: intense pulsed light; Nd:YAG: neodymium:yttrium-aluminum-garnet laser; PIH: post-inflammatory hyperpigmentation; NAPSI: Nail Psoriasis Severity Index; mNAPSI: Modified NAPSI; USG: ultrasonography; PDL: pulsed-dye laser; NS: not significant.

oxyhemoglobin and achieves greater penetration depth (≈5 mm), whereas intense pulsed light (IPL), a polychromatic source operating at 500–1200 nm, similarly induces selective photothermolysis of psoriatic vasculature [9, 10].

Despite their mechanistic rationale, data on the use of IPL and Nd:YAG specifically for nail psoriasis remain scarce [4]. The aim of this study was to directly compare their clinical efficacy by evaluating total and modified NAPSI scores and key nail findings, including onycholysis, pitting, splinter hemorrhages, red spots on the lunula, subungual hyperkeratosis, leukonychia, and salmon patches. To our knowledge, this is the first study to provide such a comparative analysis.

In the present study, IPL therapy resulted in a 45% improvement in matrix scores, 62% in nail bed scores, and 53% in total NAPSI ($P<0.05$). Consistent with our findings, previous studies have demonstrated significant improvements in both matrix and nail bed involvement with IPL therapy, accompanied by reductions in NAPSI scores [11, 12] (Table 3). Tawfik et al. similarly demonstrated significant improvements in matrix (32%), nail bed (71%), and total NAPSI scores (82%) with biweekly IPL over six months ($P<0.001$) [13]. The comparatively lower nail bed and total

NAPSI improvements in our cohort may be attributed to longer treatment intervals [13].

Nd:YAG laser therapy has consistently demonstrated clinical benefits in nail psoriasis. In the present study, significant improvements were observed in matrix and nail bed scores, accompanied by marked reductions in total and modified NAPSI ($P<0.05$). These findings are consistent with prior studies demonstrating significant reductions in NAPSI scores with Nd:YAG therapy [14-16] (Table 3). Furthermore, ultrasonographic assessments in earlier studies also supported structural improvement, including reduced nail bed and matrix thickness and dermal vascularity [17]. Notably, our work is the first to evaluate Nd:YAG efficacy using the modified NAPSI, demonstrating a 41% reduction in this parameter. Overall, the deep vascular penetration of Nd:YAG laser supports its potential as a therapeutic option for nail psoriasis [15].

In the literature, discrepancies exist regarding the clinical efficacy of Nd:YAG laser in nail psoriasis; indeed, Elwan et al. reported improvement confined to matrix involvement, which may be attributed to suboptimal laser parameters and the presence of thick toenails limiting effective beam penetration [18]. Similarly, El-Basiony et al. noted reductions in

target NAPSI and pitting that did not reach statistical significance ($P>0.05$) [17].

IPL has demonstrated efficacy in improving pitting, and in our cohort, the magnitude of this improvement appeared greater than that achieved with Nd:YAG, a finding that may reflect the relatively low vascularity of the nail matrix [11, 14, 17, 18].

Conversely, Nd:YAG significantly improved leukonychia ($P<0.05$), while IPL did not; both modalities were similarly effective in reducing red spots on the lunula. Although Tawfik et al. previously showed improvement in leukonychia with IPL, this was not observed in our cohort [13].

In this study, IPL and Nd:YAG lasers demonstrated comparable efficacy in improving onycholysis; however, only IPL yielded significant improvements in hyperkeratosis, salmon patches, and splinter hemorrhages ($P<0.05$). These findings are in line with the results reported by Morsy et al., who observed prominent improvement in onycholysis and salmon patches, with subungual hyperkeratosis showing the earliest therapeutic response following IPL therapy [11]. In contrast, variability in Nd:YAG outcomes has been described: Elwan et al. reported no significant change in salmon patches or hyperkeratosis, whereas Khashaba et al. documented significant improvement in both features using deeper-penetrating Nd:YAG parameters (5-mm spot size, 40 J/cm²), highlighting a parameter-dependent therapeutic response [14, 18].

In our cohort, pain intensity during IPL and Nd:YAG treatments was comparable, and both modalities were well tolerated, with no adverse effect or recurrence during 12-month follow-up. These observations align with previous studies reporting favorable tolerability profiles for IPL; Tawfik et al. noted only mild side effects with occasional recurrence, and Morsy et al. reported a mean VAS score of 5.8, while similar safety outcomes were documented by Shaheen et al. [11-13]. Likewise, the safety of Nd:YAG has been consistently demonstrated, with no recurrence reported over 3–12 months of follow-up [14, 15].

Given the higher vascularity of the nail bed compared with the matrix, bed-related manifestations generally exhibit a more favorable response to vascular-targeting laser systems [4, 5]. However, heterogeneity in nail characteristics, laser parameters, and the lack of standardized treatment protocols continue to limit direct comparison across studies.

The retrospective design, small sample size, lack of randomization, and analysis at the nail level without adjustment for intra-patient dependency inherently limit the generalizability of our findings and may increase the risk of type I error, particularly in the absence of multiple-comparison corrections such as Bonferroni adjustment. Additionally, evaluating multiple nails from the same patient may introduce intra-individual variability.

Conclusions

This study suggests that both IPL and Nd:YAG lasers may serve as practical therapeutic options in isolated or refractory nail psoriasis, especially in individuals unable to tolerate systemic treatments. These modalities may also offer value as adjunctive therapies; however, larger, prospective, rigorously controlled studies are needed to confirm long-term efficacy, optimize treatment protocols, and better define appropriate patient selection.

References

1. Canal-García E, Bosch-Amate X, Belinchón I, Puig L. Nail Psoriasis. *Actas Dermosifiliogr*. May 2022;113(5):481–490. DOI:10.1016/j.ad.2022.01.006
2. Ji C, Wang H, Bao C, et al. Challenge of Nail Psoriasis: An Update Review. *Clin Rev Allergy Immunol*. Dec 2021;61(3):377–402. DOI:10.1007/s12016-021-08896-9
3. Mease PJ. Measures of psoriatic arthritis: Tender and Swollen Joint Assessment, Psoriasis Area and Severity Index (PASI), Nail Psoriasis Severity Index (NAPSI), Modified Nail Psoriasis Severity Index (mNAPSI), Mander/Newcastle Enthesitis Index (MEI), Leeds Enthesitis Index (LEI), Spondyloarthritis Research Consortium of Canada (SPARCC), Maastricht Ankylosing Spondylitis Enthesis Score (MASES), Leeds Dactylitis Index (LDI), Patient Global for Psoriatic Arthritis, Dermatology Life Quality Index (DLQI), Psoriatic Arthritis Quality of Life (PsAQOL), Functional Assessment of Chronic Illness Therapy-Fatigue (FACIT-F), Psoriatic Arthritis Response Criteria (PsARC), Psoriatic Arthritis Joint Activity Index (PsAJAI), Disease Activity in Psoriatic Arthritis (DAPSA), and Composite Psoriatic Disease Activity Index (CPDAI). *Arthritis Care Res (Hoboken)*. Nov 2011;63 Suppl 11:S64–85. DOI:10.1002/acr.20577
4. Jaalouk D, Algarin YA, Pulumati A, Humeda J, Nouri K. Lasers for the treatment of nail psoriasis: a systematic review. *Int J Dermatol*. Nov 2024;63(11):1484–1494. DOI:10.1111/ijd.17304
5. Wiznia LE, Quatrano NA, Mu EW, Rieder EA. A Clinical Review of Laser and Light Therapy for Nail Psoriasis and Onychomycosis. *Dermatol Surg*. Feb 2017;43(2):161–172. DOI:10.1097/dss.0000000000000841
6. Heidemeyer K, Kulac M, Sechi A, Cazzaniga S, Naldi L. Lasers for the treatment of psoriasis: a systematic review. *Expert Rev Clin Immunol*. Jul–Dec 2023;19(7):717–744. DOI:10.1080/1744666x.2023.2205640
7. Hern S, Stanton AW, Mellor RH, Harland CC, Levick JR, Mortimer PS. In vivo quantification of the structural abnormalities in psoriatic microvessels before and after pulsed dye laser treatment. *Br J Dermatol*. Mar 2005;152(3):505–11. DOI:10.1111/j.1365-2133.2005.06435.x
8. Gratz BW, Resnick GF, Etcheverry MJ, Geng X, Stringer TP. Pulsed dye laser for nail psoriasis: A systematic review and meta-analysis. *J Am Acad Dermatol*. Feb 22 2025. DOI:10.1016/j.jaad.2024.12.051
9. Meesters AA, Pitassi LH, Campos V, Wolkerstorfer A, Dierickx CC. Transcutaneous laser treatment of leg veins. *Lasers Med Sci*. Mar 2014;29(2):481–92. DOI:10.1007/s10103-013-1483-2

10. Babilas P, Schreml S, Szeimies RM, Landthaler M. Intense pulsed light (IPL): a review. *Lasers Surg Med.* Feb 2010;42(2):93–104. DOI:10.1002/lsm.20877
11. Morsy EE, Mohamed R, Omar SI. Intense pulsed light versus pulsed dye laser in the treatment of nail psoriasis: Intra-patient left to right comparative controlled study. *Indian J Dermatol Venereol Leprol.* Nov–Dec 2024;90(6):713–721. DOI:10.25259/ijdv1_429_2023
12. Shaheen MA, Dakhli AO, Hassen SI. Comparison between the efficacy of Intense Pulsed Light (I.P.L.) versus Photo-Dynamic Therapy (P.D.T.) with methylene-blue in the treatment of psoriatic nails. *Photodiagnosis Photodyn Ther.* Mar 2023;41:103298. DOI:10.1016/j.pdpdt.2023.103298
13. Tawfik AA. Novel treatment of nail psoriasis using the intense pulsed light: a one-year follow-up study. *Dermatol Surg.* Jul 2014;40(7):763–8. doi:10.1111/dsu.0000000000000048
14. Khashaba SA, Gamil H, Salah R, Salah E. Efficacy of long-pulsed Nd-YAG laser in the treatment of nail psoriasis: a clinical and dermoscopic evaluation. *J Dermatolog Treat.* Jun 2021;32(4):446–452. DOI:10.1080/09546634.2019.1668908
15. Kartal SP, Canpolat F, Gonul M, Ergin C, Gencturk Z. Long-Pulsed Nd: YAG Laser Treatment for Nail Psoriasis. *Dermatol Surg.* Feb 2018;44(2):227–233. DOI:10.1097/dss.0000000000001294
16. Roter G, Szczerkowska-Dobosz A, Nowicki RJ. Treatment of nail psoriasis with pulsed dye laser versus combined pulsed dye and Nd:YAG lasers-An inpatient left-to-right study. *Lasers Surg Med.* Jul 2022;54(5):688–692. DOI:10.1002/lsm.23537
17. Hesham Ali Elwan Y, Abdel Azim A, Starace M, Shawky Abd Elhafiz H. Nd:YAG Laser in the Treatment of Nail Psoriasis: Clinical and Dermoscopic Assessment. *Dermatol Pract Concept.* Mar 2021;11(2):e2021140. DOI:10.5826/dpc.1102a140
18. El-Basiony MAS, El-Komy MHM, Samy NA, et al. Long-pulsed nd: YAG laser treatment of nail psoriasis: clinical and ultrasonographic assessment. *Arch Dermatol Res.* Jun 8 2024;316(7):365. DOI:10.1007/s00403-024-03036-7